



## Case Report

# Chronic axillary web syndrome: 83 months post lumpectomy–A Case report

Laura F Rezende<sup>1\*</sup>, Ricardo Laier Franco<sup>2</sup>, Vanessa Fonseca Vilas Boas<sup>1</sup>, Juliana Lenzi<sup>2</sup>, and Regiane Luz Carvalho<sup>1</sup>

<sup>1</sup>Physical Therapy School, University Center of the Associated Teaching Faculties-FAE, São João da Boa Vista-SP, Brazil

<sup>2</sup>Medical School, State University of Campinas-UNICAMP, Campinas-SP, Brazil

Received: 23 January, 2020

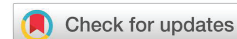Accepted: 24 April, 2020

Published: 25 April, 2020

\*Corresponding author: Laura F Rezende, Physical Therapy School, University Center of the Associated Teaching Faculties-FAE, São João da Boa Vista-SP, Brazil, Tel/Fax: +55 19 3638 0240; E-mail: prom\_hg@yahoo.com

Keywords: Axillary web syndrome; Breast cancer; Axillary lymphadenectomy

<https://www.peertechz.com>



## Abstract

**Introduction:** Axillary Web Syndrome (AWS) is well described until 3 months postoperative breast cancer surgery.

**Methods:** We report a case of a 47 years old patient that arrived our rehabilitation service with pain and limited shoulder range of movement in the ipsilateral side of a breast cancer surgery.

**Results:** An Axillary Web Syndrome was diagnosed 83 months after the surgery.

**Conclusion:** It is important to mention that AWS might persist for a long time and also affect patients a long time after the surgery.

## Introduction

Currently, axillary lymphadenectomy (ALN) is a staging procedure for breast cancer surgery and also an important prognostic factor. However some complications such as Axillary Web Syndrome (AWS) might happen. AWS is a common complication in the early postoperative breast cancer surgery. The incidence is variable probably because it is misreported and misdiagnosed. The features of AWS are fibrotic and painful bands or “cords” in the axilla, that might extend along the anterior and medial part of the arm, across the antecubital fossa and may reach the radial part of the wrist and the base of the thumb. It also might be found in the lateral chest wall, breast and abdomen [1,2].

## Case report

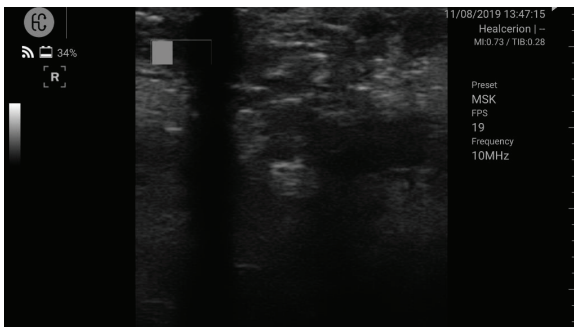
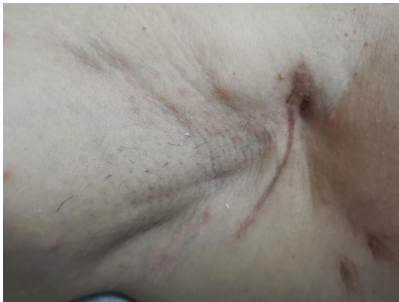M.C.L., female, 47 years old, married, two sons, BMI 25.8 kg/m<sup>2</sup>, arrived our rehabilitation service complaining of intense

pain in the breast and in the axilla, mainly around the axilla scar, where ALN was done. She was submitted in 12/18/2012 to right breast lumpectomy and axillary clearance. Histopathology showed a 1.9 x 1.7 cm ductal invasive carcinoma and 4 positive lymph nodes in 40. After the surgery she received adjuvant chemotherapy, radiotherapy and hormonotherapy (tamoxifen 20mg). The physical examination showed limited shoulder range of movement (85 degrees of flexion and 70 degrees of abduction), with the presence of two palpable fibrous cords on the skin surface originating from the axilla (coincident with the axillary scar with significant tissue fibrosis), extending from the medial region of the arm to the elbow with also had important lymphatic stasis in the right breast. M.C.L. was unable to perform shoulder and elbow flexion simultaneously due to pain.

An ultrasound with Healcerion Sonon 300L<sup>®</sup> device was done by a technologist using a 10MHz probe to complement the



diagnose. Ultrasound showed an hypoechoic image with strong posterior shadowing. The exame also showed deformation of the dermis with shoulder abduction. The hypoechoic image was compressible with pressure.



## Discussion

AWS is used to develop in the majority of cases within three months following ALN, more often in first post-operative week<sup>1</sup>. A recent prospective study suggested that 94% of patients who developed AWS diagnosed it within the first month. However, there are some reports showing that AWS may appear or persist well beyond that 12-week window to as late as 2 years after axillary surgery [3]. The incidence is higher in surgery with axillary clearance (36%–72%), compared with surgery with sentinel lymph node biopsy (11%–58%) [4].

Typically, AWS occurs within the first 8 weeks after axillary surgery with symptoms resolving within the first 12 weeks postoperatively [5]. The recurrence is not common, but late incidence of AWS was 16.2% at 3 months, 23.4% at 6 months, 29.2% at 12 months, and 36.2% at 24 months post-operative in a prospective study [6]. One study showed a 50% prevalence of AWS at 18 months after surgery [2].

## Conclusion

As far as we know there are no report published showing a so late case of AWS. It is important to mention that AWS might persist for a long time and also affect patients a long time after the surgery. Chronic AWS occurs with limited shoulder range of movement and intense pain. Due to this it is very important the diagnose and treatment of AWS to improve the quality of life in patients after breast cancer treatment.

## References

1. Yeung WM, McPhail SM, Kuys SS (2015) A systematic review of axillary web syndrome. *J Cancer Surviv* 9: 576-598. [Link: https://bit.ly/2VyXPri](https://bit.ly/2VyXPri)
2. Koehler LA, Blaes AH, Haddad TC, Hunter DW, Hirsch AT, et al. (2015) Research report movement, function, pain, and postoperative edema in axillary web syndrome. *Phys Ther* 95: 1345-1353. [Link: https://bit.ly/2yFnJR6](https://bit.ly/2yFnJR6)
3. Baggi F, Nevola Teixeira LF, Gandini S (2018) Axillary web syndrome assessment using a self-assessment questionnaire: a prospective cohort study. *Support Care Cancer* 26: 2801-2807. [Link: https://bit.ly/3bE3DVQ](https://bit.ly/3bE3DVQ)
4. Koehler LA, Haddad TC, Hunter DW, Tuttle TM (2019) Axillary web syndrome following breast cancer surgery: symptoms, complications, and management strategies. *Breast Cancer (Dove Med Press)* 20: 13-19. [Link: https://bit.ly/2Kzyd7q](https://bit.ly/2Kzyd7q)
5. O'Toole J, Miller CL, Specht MC (2013) Cording following treatment for breast cancer. *Breast Cancer Res Treat* 140: 105-111. [Link: https://bit.ly/2Kzy7N6](https://bit.ly/2Kzy7N6)
6. Harris SR (2018) Axillary Web Syndrome in Breast Cancer: A Prevalent But Under-Recognized Postoperative Complication. *Breast Care (Basel)* 13: 132-135. [Link: https://bit.ly/35bkahS](https://bit.ly/35bkahS)

Discover a bigger Impact and Visibility of your article publication with Peertechz Publications

### Highlights

- ❖ Signatory publisher of ORCID
- ❖ Signatory Publisher of DORA (San Francisco Declaration on Research Assessment)
- ❖ Articles archived in worlds' renowned service providers such as Portico, CNKI, AGRIS, TDNet, Base (Bielefeld University Library), CrossRef, Scilit, J-Gate etc.
- ❖ Journals indexed in ICMJE, SHERPA/ROMEO, Google Scholar etc.
- ❖ OAI-PMH (Open Archives Initiative Protocol for Metadata Harvesting)
- ❖ Dedicated Editorial Board for every journal
- ❖ Accurate and rapid peer-review process
- ❖ Increased citations of published articles through promotions
- ❖ Reduced timeline for article publication

Submit your articles and experience a new surge in publication services (<https://www.peertechz.com/submission>).

Peertechz journals wishes everlasting success in your every endeavours.

**Copyright:** © 2020 Rezende LF, et al. This is an open-access article distributed under the terms of the Creative Commons Attribution License, which permits unrestricted use, distribution, and reproduction in any medium, provided the original author and source are credited.

**Citation:** Rezende LF, Franco RL, Vilas Boas VF, Lenzi J, Carvalho RL (2020) Chronic axillary web syndrome: 83 months post lumpectomy-A Case report. *J Nov Physiother Phys Rehabil* 7(1): 013-014. DOI: <https://dx.doi.org/10.17352/2455-5487.000069>